price:

NO: 8

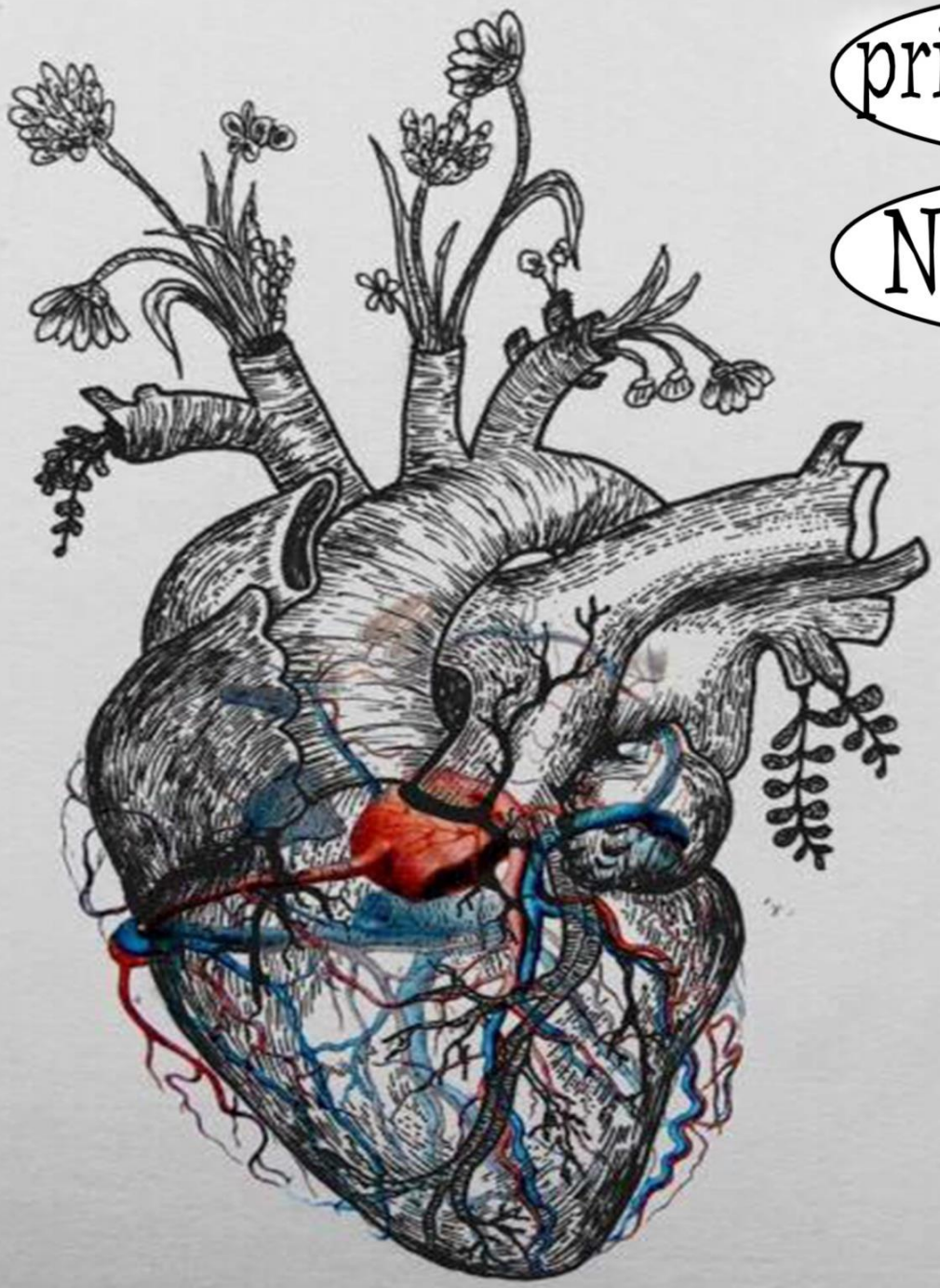

# CVS

sub-system: Physiology - 3

lecture: ECG

Doctor: د. محمد جعفر

Date: 17/3/2016

Done by: Turquoise Team

Hello, ☺

Please, do not listen to the record while studying.

Let's start.

The standard EKG consists of 12 leads, with each lead determined by the placement and orientation of various electrodes on the body. Each lead views the heart at a unique angle, enhancing its sensitivity to a particular region of the heart at the expense of others. The more views, the more information provided.

These 12 leads are divided into:

1. Bipolar leads: (also called bipolar limb lead): which includes: lead I, lead II, and lead III.
2. Unipolar leads: which are subdivided into:
   A. unipolar limp leads: (AVR, AVL & AVF).
   B. unipolar chest leads: (V1, V2, V3, V4, V5 and V6).

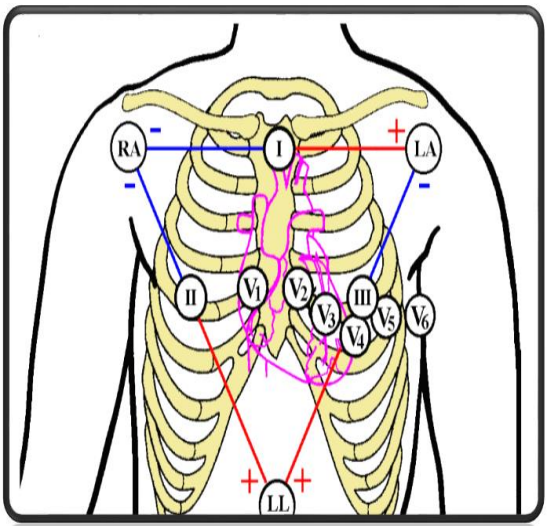


In unipolar chest leads we have 6 electrode, and we put them on the anterior surface and on the left lateral wall of the chest like this.

These electrodes are named V (for vector) with a number from 1-6; they also can be named C (stand for chest) with a number from 1-6 (so C2 is the same as V2).

The locations of these electrodes, as shown:

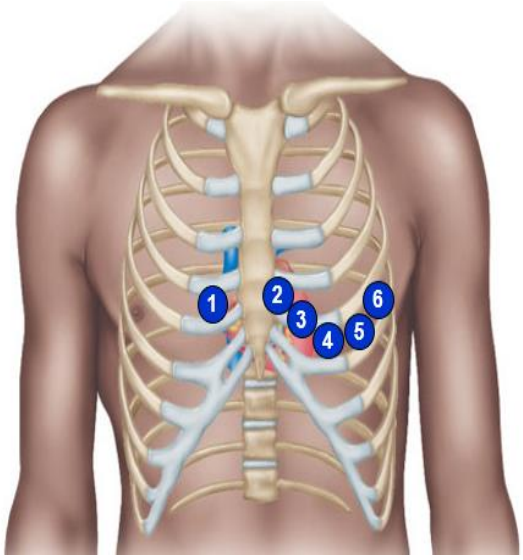


V1 = 4th intercostal space, right of the sternum.
V2 = 4th intercostal space, to the left of the sternum, on the same level of V1.
V3 = between V2 & V4.
V4 = mid clavicular line (If you draw a line from the middle of the clavicle to the 5th intercostal space), that is the V4 and it is exactly just beneath the nipple.
V5 = 5th intercostal space, anterior axillary line.
V6 = 5th intercostal space, Middle axillary line.

So, V1 and V2 ➔ in the 4th intercostal space and V4, V5, and V6 ➔ in the 5th intercostal space and V3 between V2 and V4.

We consider these electrodes as the positive electrode.

We use different leads because the heart has a big mass and we need to know where the problem is.

In Unipolar limb lead, we examine the heart side by side, we examine the right side in relation to the zero (the summation of lead I, lead II and lead III), the left side in relation to the zero and the inferior side in relation to the zero.

> We call the summation of lead I, lead II and lead III (which is equal to zero): the indifferent electrode and we consider it as the negative electrode, it has no voltage (zero) but nevertheless, we consider it negative.
>
> هون الدكتور قصده انو محصلة ال ٣ ليدز تساوي صفر
> القانون هو ليد١+ليد٣=ليد٢
> ومنه ← ليد١+ ليد٣- ليد٢= صفر

For the right side we used the right arm as the active (positive) electrode, and compared it to the zero, and the left arm for the left side and compare it to the zero, and the left leg for the inferior side and compare it to the zero and these are the **UNIPOLAR limp leads**.

So, we have AVR (for the right side) ➔ which stand for Augmented Vector of the right Arm,
AVL (for the left side) ➔ Augmented Vector of the left Arm, and
AVF (for the inferior side) ➔ Augmented Vector of the left Foot.

In AVF, what we are examining is the inferior part of the left ventricle.

In this system (Augmented unipolar limp leads), and in this type of recording, two of the limbs are connected to the negative electrode, and the third limb is connected to the positive electrode (When the positive terminal is on the right arm, the lead is known as the AVR lead, when it's on the left arm, it is known as the AVL lead, and when it's on the left leg, it is known as the AVF lead).

Augmentation means amplifying, so, by doing this: (connecting two limb with negative and one with positive), we will increase the amplitude of the voltage.

Now we have 12 leads: 3 bipolar leads, 3 unipolar limp leads, and 6 unipolar chest leads.
So for each patient we record 12 leads to have an idea where the problem is.

And what is the most important part of the heart? The left ventricle.

If there is a problem in the left ventricle, it will be in the function of the ventricle, not in excitation, so it is not necessary to affect all of the heart, so we can see that in the ECG and it will give us an idea of what the problem is.

If we have a problem in the excitation it will affect all of the heart.

So when you record the ECG you are going to connect the right arm, left arm, the left leg and the right leg (for earthing), then we connect chest lead (v1, v2, v3, .., v6).

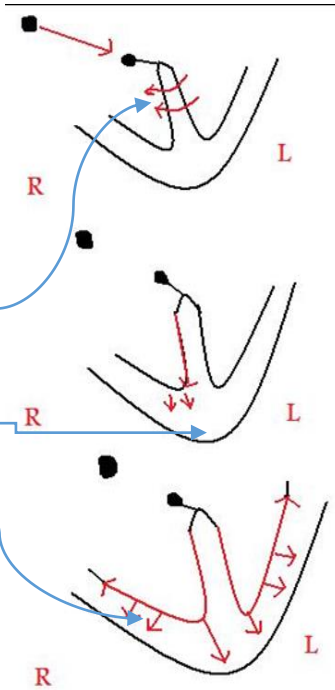


The direction of excitation, (which is the direction of the conductive tissue or the direction of the current): from the AV node to the AV bundle and then to the branches and then to the Purkinje fibers.

The first part of the ventricle that will be excited is the base of the septum and the direction of excitation is from the left to the right, then it will go from the base to the apex then from the apex to the lateral wall.

So, Base ➔ apex ➔ lateral wall

Because of the presence of Purkinje fibers, all of this will develop in a very short period of time.

You will see that when you record the ECG, if you take the excitation in the SA node as zero time, by the time it reaches the AV node and both of the atria become depolarized, it will take 30 milliseconds (from SA node to AV node and the time for depolarization of both of the atria).

Now, in the AV node there is a delay which equal to 130 milliseconds.

The excitation of ventricles will begin after a 160ms, and the ventricles excitation requires 60ms, so after 220 ms (from the beginning of AP in SA node) both ventricles will be totally excited.

So the total time for the excitation to start in the SA node until the stimulation of both ventricles takes 220 milliseconds.

So when we record the ECG we suppose to see depolarization of atria, plateau of atria, repolarization of atria, depolarization of ventricles, plateau of ventricles, and repolarization of ventricles.

Note: To know where the $4^{th}$ intercostal space is, we go to the sternal angel ➔ $2^{nd}$ intercostal space ➔ $3^{rd}$ ➔ $4^{th}$.

## Normal ECG

This is how normal ECG looks like :O

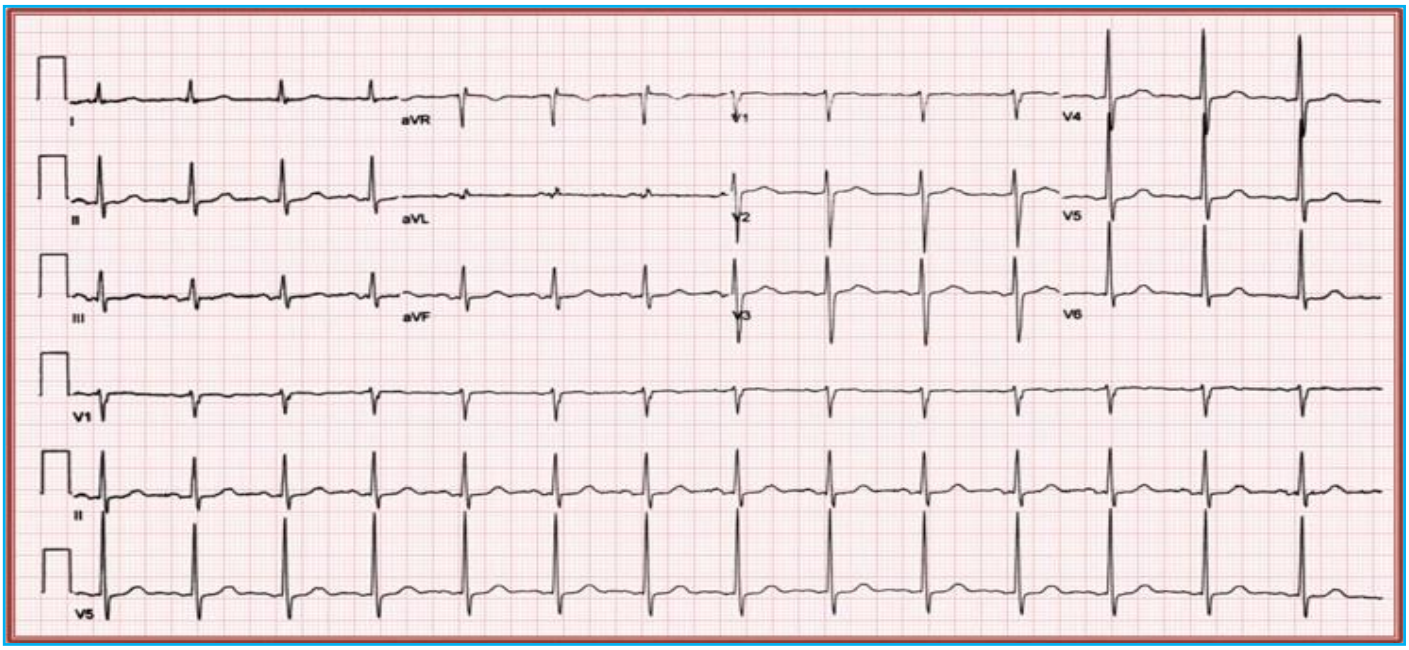


We will take one of these repeated units and go through its details.

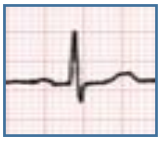

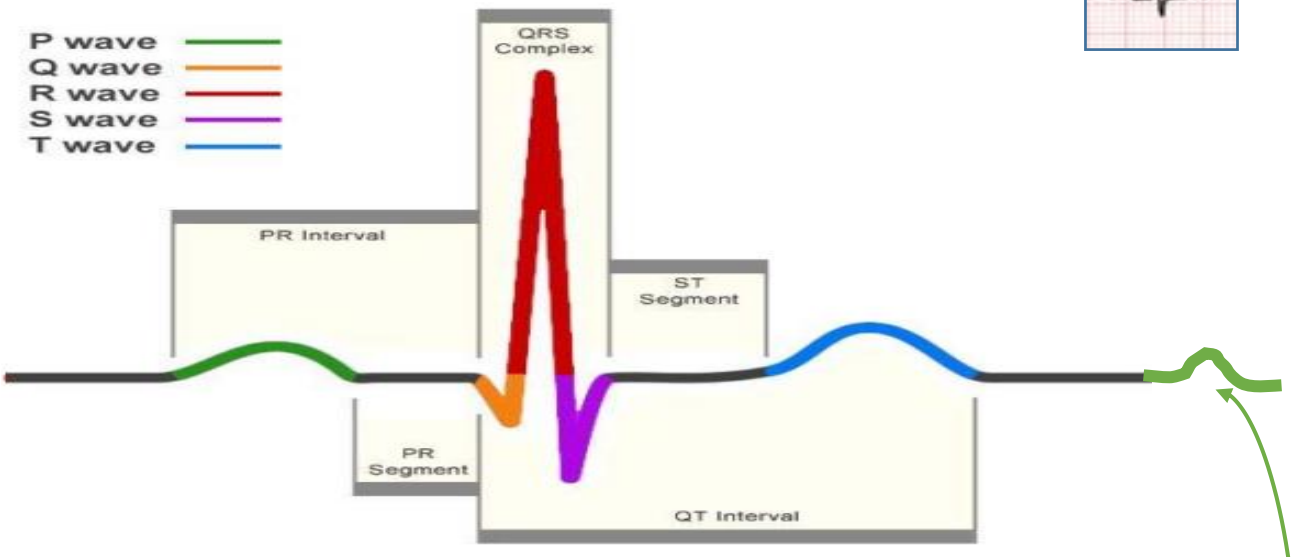


P wave: represents the depolarization of the atria.

PR segment: represents the plateau of the atria (from the end of p wave to the beginning of QRS).

QRS: represents the ventricles' depolarization.

ST segment: represents the plateau of the ventricles.

T wave: represents the repolarization of the ventricles.

U wave: **rarely appears**, and it represents the repolarization of the papillary muscle.

The PR segment represents the contraction of the atria, it is called isoelectric line (which means: straight line) ➔ both electrodes have the same polarity (earthier + or – or resting).

In the QRS complex:
Q ➔ is negative (represents the depolarization of the base of the septum).
R ➔ is positive.
S ➔is negative.



QRS complex doesn't show atrial repolarization, but during it, atrial repolarization happens. So, 2 things happen at the same time: atrial repolarization and the depolarization of ventricle. (We can't see the repolarization of the atria because its amplitude is very small, so what we are seeing is the large amplitude (depolarization of ventricles)).

Now if we want to see the repolarization of atria we can put a catheter on the atria, stimulate it and see the repolarization.

Also we can't detect the action potential of the SA node because its amplitude is very small (we can put catheter on it and detect its AP).

Sometimes in QRS, we see R and S only without S and sometime Q and R only without S, it depend on the position of the electrode, and this is normal.

**ST segment**: represent the contraction of the ventricles.

**Intervals in ECG:** (Interval mean duration, or time)

1. **PR interval**: from the beginning of the P wave until the beginning of QRS complex.

It represents the duration of the impulse to start in the SA node until it reaches the ventricles (including the delay that happens in the AV node).

In average it equals: 160 millisecond. And the normal range for it is from 120 to 200 millisecond.

This time includes 2 things: depolarization of atria &the plateau of atria.

When we are sleeping: the heart rate decreases, so the PR interval will increase.

When we do exercise, anxiety: the heart rate will increase, so the PR interval will be shorter.

2) QT interval: From the beginning of QRS (beginning of the ventricular depolarization) until the end of T wave (end of ventricular repolarization).

It represents the electrical depolarization, plateau and repolarization of the ventricles ➔ so it is the AP of the ventricles.

It is about 350 milliseconds

In heart diseases, like: MI (myocardial infarction) & angina, this interval will be increased (because the wash out of ions will be abnormal {s problem in the sodium potassium pump}).

3) TP interval: from the end of the T wave (end of ventricular repolarization) to the beginning of the P wave (beginning of atrial depolarization).

This time represents the resting potential, during this interval there is a leakage of the Na in the **SA node**, not in the ventricles or atria, waiting for the threshold to be reached to the next beat. (All channels will be closed).

So, we have three isoelectric lines: PR segment, ST segment and TP interval.

Positive value (or positive voltage) means that: the ECG line will be UP the zero line, like this:

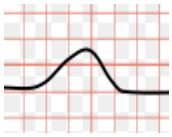

And negative value (or voltage) means that that: the ECG line will be below the zero line, like this:

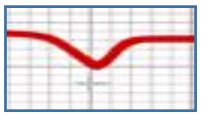

Now, Why the Q and S are negative??

Remember that if the current is going toward the positive electrode it will give you + voltage (the line will go UP) and vice versa.

So any current going towards the **positive** electrode, will have a positive value, while any current going away from the **positive** electrode, will have a negative value. On the other hand, any current going towards the **negative** electrode will have a negative value, and any current going away from the **negative** electrode will have a positive value.

If we are talking about V3 (which positive electrode located between 4$^{th}$ and 5$^{th}$ intercostal space, to the left side of the sternum), if the current goes to the left side of the body (towards the positive electrode), it will be positive, and if it goes to the left, it will be negative.

Now, why is Q negative? Simply, because the current is going away from the positive electrode.
Why is R positive? The current is going to the positive electrode.
BUT, HOW?

We know the QRS represents ventricular depolarization, the first part of the ventricles to be stimulated is the base of the septum, and it gets stimulated from the left to the right (away from the positive electrode), and from endocardium to the epicardium (from inside to the outside). So, the overall direction of stimulation (current), is from left to right ➔ away from the positive electrode ➔ it will be negative.

So, Q wave represents the depolarization of the base of the septum.

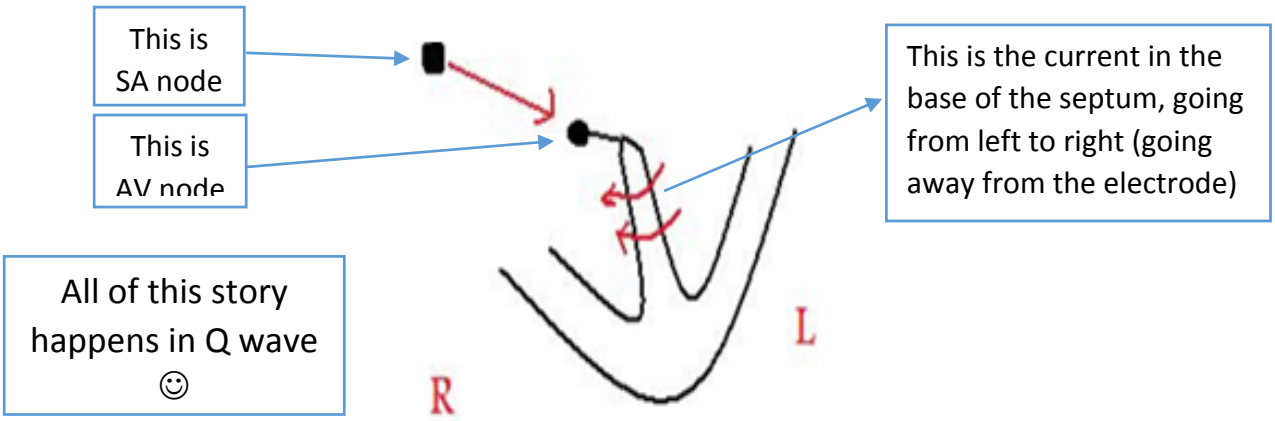


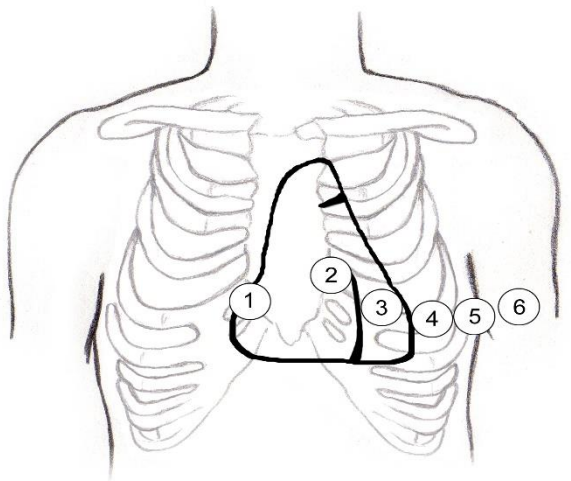


This diagram helps you to imagine where the positive electrode of V3 is located; it is to the left of the septum, so anything that goes away from it (to the right) will give a negative voltage. ☺

Now, the base of the septum will transfer the current to the apex of the heart, and the current will go from the apex to the lateral wall of the ventricles (toward the positive electrode), so it will give a positive voltage.

And this is the R wave (depolarization of the lateral wall of the ventricles), and because its direction is toward the positive electrode, it will give a positive deflection.

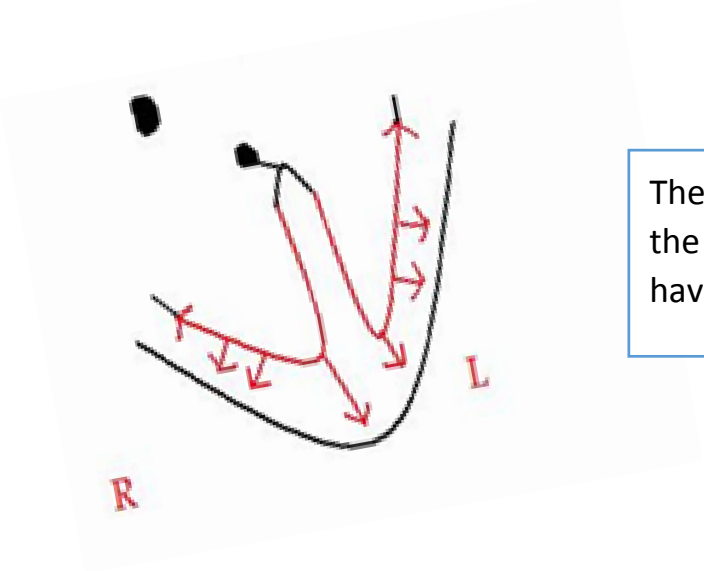


The current direction is toward the positive electrode, so it will have a positive deflection.

So it depends on where the electrode in relation to the current direction is.

The right side of the body is always negative and the other side is positive.
As you moves the positive electrode to the right, negativity will increase, and positivity will decrease, and vice versa.

If you are moving the positive electrode to the left side of the body ➔ positivity will increase (R will increase).

And when you move the positive electrode to the right side ➔ negativity will increase (S will increase).

I hope it is clear now.

If you put the electrode near the septum (septum is on the right side of V3)➔ negativity will be high ➔ high S, and positivity will be low ➔ small R.

If you shift the electrode to the left (away from septum, and toward the positive electrode) ➔ negativity will decrease and positivity will increase.

Small R and large S ➔ in V1 (because it's in the right), then R will gradually increase, and S will gradually decrease as the positive electrode moves to the left side (when you move from V1 toward V6).

Always: right side is the negative and the other side is positive.

As you're going to the right (negative side) S will gradually increase.
As you're going to the left (positive side) R will gradually increase and S will gradually decrease (from V1 to V6).

So R will be at the maximum in ➔ V6, and minimum in ➔ V1 or V2
S will be at the maximum in ➔ V1 or V2, and minimum in ➔ V6

In lead I (from negative {right arm} to positive {left arm}) you will have positive deflection (increase).

And the same thing in lead II and lead III (from – to + ➔ positive deflection).

But the difference will be in the amplitude ➔ the maximum amplitude will be in lead II and the minimum in lead III, and if you take the summation (المحصلة وليس الجمع) {lead I + lead III – lead II} of the three, it will be ZERO, and the voltage of lead II equals the summation of lead I and lead III {lead I + lead III = lead II}.

Why does lead II have the maximum deflection? Because the direction of its current is always from right to left and it is parallel to the direction of the current.

Now if you take the unipolar limb leads (you take one arm as positive and the 3 leads as negative);

When we take AVR (for example), we consider it as the positive electrode, the direction of current from right to left, so the impulse is going away from the positive.

In AVR, the positive electrode is in the right arm.

In AVR the current goes away from the positive ➔ all the waves in AVR are negative.

So normally, all of the waves in AVR are negative (because the current all the way go away from the positive).

Normal AVR ECG

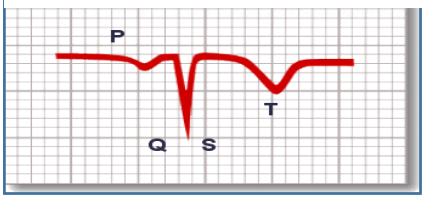


In other leads, any negative waves are significant; it is abnormal

Now, why is T wave positive?

(The next explanation is the what the doctor said, however, it is not clear at all, so I added some Information in the Box bellow. So if you didn't understand what is written here, read what in the Box and it should help you).

First, theoretically, T wave should be negative, WHY?

When all the ventricles are depolarized, the negativity will be outside, if the repolarization starts again in the same place, the outside will become positive.

If the repolarization starts from the inside (which was – and became +), the direction of repolarization will be away from the positive ➔ so it will be negative (but this is not the case), why?

During the depolarized state, + will be inside and – will be outside.

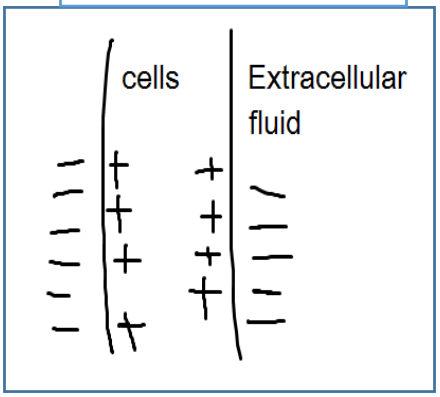

Because the repolarization of the ventricles doesn't start in the same direction, the direction of repolarization of the ventricles starts from the outside to the inside (exactly opposite to the direction of depolarization), WHY?

In the contraction of the heart, the force of contraction inside is too much, so the blood vessels will be constricted, so the wash out of the ions inside is less than the wash out of ions outside, that's why it becomes positive. (This is what the doctor said, however, the next box shows another way to understand it {the information inside the box wasn't mentioned by the doctor, but I added them for clarifying}).

The effects of repolarization on the EKG are similar to those of depolarization, except that the charges are **reversed** (in depolarization, positive go inside the cell, while in repolarization, positive go outside the cell). A wave of repolarization moving toward a positive electrode inscribes a **negative** deflection on the EKG. A wave of repolarization moving away from a positive electrode produces a **positive** deflection on the EKG.

يعني عكس الحالة الأولى.

Here you can find some nice videos, which will help you to understand this subject very well.

https://goo.gl/ViFsba

And we are DONE ☺

Done BY: Ahmed Ibeid.

**Edited by: Alina Salaimeh**